

Nevus Sebaceous of Jadassohn – A Rare Case Report

Kumar Prateek¹, Meena Rinoo Banwarilal², Meenakshi Garg³, Shyam Sundar Chaudhary⁴

Department Of Dermatology, Venereology & Leprosy, Rajendra Institute Of Medical Sciences, Ranchi, Jharkhand, India,

Abstract: *Nevus sebaceous also known as Nevus sebaceous of Jadassohn [NS] is an epidermal nevi predominantly congenital sebaceous hamartoma. It is composed of sebaceous glands and commonly presents as single yellowish plaque over the head and neck. The morphology of the lesion changes around puberty when it becomes thickened and nodular. Sebaceous nevus has definite potential for malignant transformation in later life therefore prophylactic surgical excision is recommended in childhood. We report this case in a twelve year old boy with a plaque over the posterior surface of the right ear and had multiple soft digitate projections growing over it since last one year.*

Keywords: *Nevus sebaceous, Sebaceous glands, Plaque ,digitate projections*

I. Introduction

Sebaceous naevus or naevus sebaceous is a well circumscribed hamartomatous lesion comprised predominantly of sebaceous glands. Majority of the sebaceous naevi occur sporadically but some familial cases have been reported [1]. The lesion usually starts as an isolated plaque at birth or may develop later and remains unchanged until puberty when it becomes thickened and more elevated under the influence of sex hormones [2]. Malignant transformation is a well established complication of sebaceous naevi, however the life time risk is estimated to be less than 5% [3,4]. The majority of sebaceous naevi occur on head and neck favouring scalp, ears, forehead and skin of central part of the face. We report a case of nevus sebaceous in a twelve year old boy over the posterior surface of right ear and with multiple soft digitate projections growing over it since last one year.

II. Case Report

A 12 year old boy presented with a one year history of an asymptomatic raised lesion over the posterior surface of right ear. Thorough history revealed that there was a small yellowish spot at the site of lesion since the age of 4 years which remained unchanged till one year back when it started increasing in size. There was no history of other skin or systemic diseases. Examination revealed a whitish grey plaque (2.5cm x 1cm) over posterior surface of the right ear (Fig.1 & 2). Multiple skin coloured to dark brown soft digitate projections were seen not only over the plaque but also over the surrounding normal skin. General physical and systemic examination were within normal limits. Neurological, ophthalmological and musculoskeletal examination were normal. X-ray of facial bones and chest x-ray were normal. A full depth skin biopsy was taken from the outer part of the lesion with a 3mm disposable skin biopsy punch and sent for histopathological examination. The histopathology revealed papillomatous hyperplasia of the epidermis and numerous mature and immature sebaceous glands and apocrine glands in dermis (Fig. 3). On the basis of history, clinical examination and histopathology, a diagnosis of sebaceous nevus was made and surgical excision of the lesion was done in the surgery department.

III. Discussion

Nevus sebaceous is usually present at birth; common locations are head and scalp and it usually manifests as a well defined grey plaque with yellow to orange hue [5,6]. In the infantile stage, the epidermis is only slightly acanthotic and may be hyperpigmented [7].The hair follicles are small, incompletely formed, and seen as solid cords of undifferentiated basaloid cells. The sebaceous glands are inconspicuous.

The second stage of the nevus occurs during adolescence and is characterized by an increase in the size of the lesion, which may show smooth surface nodularities or verrucous hyperkeratosis [5,8].Histological findings show verrucous epidermal hyperplasia. This overlaps with the histologic picture of epidermal nevus and can be differentiated from it by the presence of malformations of the dermis, most prominently hyperplasia and malpositioning of the sebaceous glands [9].The hair follicles remain small and primordial. The sebaceous glands are now numerous and hyperplastic. Many of the lesions may also exhibit apocrine glands with dilated lumina and eccrine gland hyperplasia.These divergent features point to a common embryological origin of the pilosebaceous-apocrine unit,and any of them may predominate over the other.

The third stage occurs during the adult life when epidermal hyperplasia, large sebaceous glands, and ectopic apocrine glands are seen histologically. The hair follicles remain primordial[10]. In the third stage variety of benign and malignant adnexal tumors may appear. Benign tumors are seen in about 13%, while malignancies are seen in 1% of the cases of NS [11]. Trichoblastoma and syringocystadenoma papilliferum are the commonest benign tumors seen [5]. Malignant cutaneous neoplasms are less common, which includes basal cell carcinoma and sometimes squamous cell carcinoma[12,13].

IV. Conclusion

NS is a hamartoma consisting of various elements indigenous to the organ and not merely the sebaceous units. Normal terminal hair follicles are characteristically absent in the lesion although the same may be seen in rest of the epidermis, a feature of diagnostic importance, not usually highlighted in literature. Though malignancy is uncommon, a cautious histological examination is mandatory, especially if there are clinical changes in a lesion.

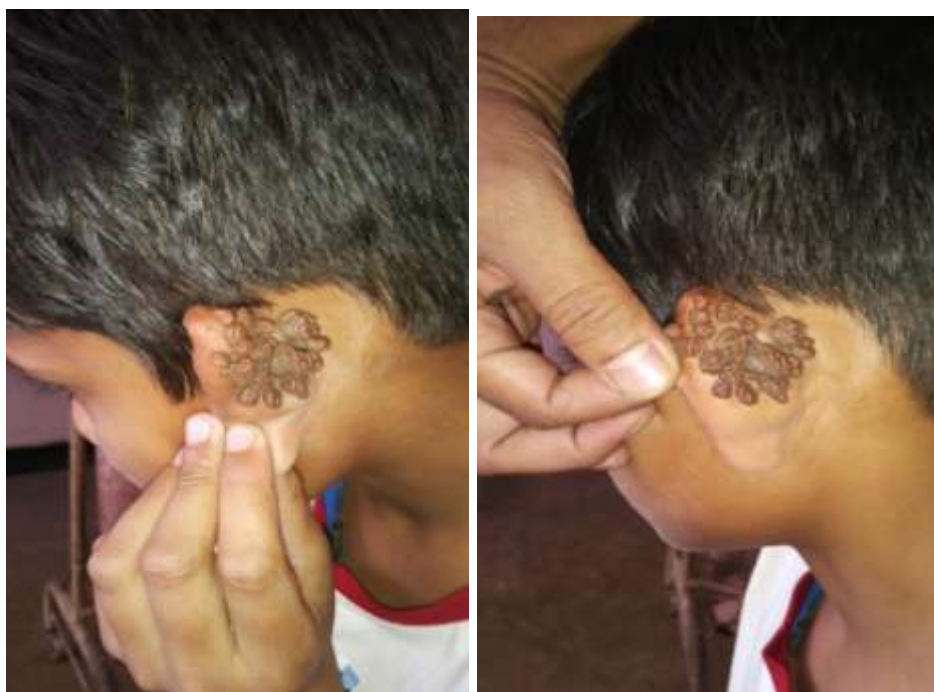

Figure 1 and 2 showing whitish grey plaque with multiple skin coloured to dark brown soft whorled masses over it.

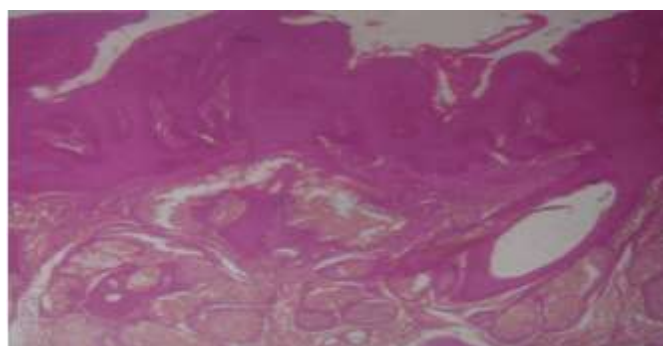


Figure 3 HPE showing papillomatosis of epidermis; mature and immature sebaceous glands and apocrine glands.

References

- [1]. Sahl WJ: Familial nevus sebaceous of Jadassohn: occurrence in three generations. *J Am Acad Dermatol* 1990; 22: 853-854.
- [2]. Hamilton KS, Johnson S, Smoller BR: The role of androgen receptors in the clinical course of nevus sebaceous of Jadassohn. *Mod Pathol.* June 2001; 14: 539-542.
- [3]. Kumar K, Garg RK: Naevus sebaceus of Jadassohn. *Indian J Dermatol Venereol Leprol* 1973; 39: 5-9.
- [4]. Goldstein GD, Whitaker DC, Argenyi ZB, Bardach J: Basal cell carcinoma arising in naevus sebaceus during childhood. *J Am Acad Dermatol* 1988; 18: 429-430.

- [5]. Mehregan AH. Sebaceous tumors of the skin. *J Cutan Pathol* 1985;12:196-9.
- [6]. Rulon DB, Helwig EB. Cutaneous sebaceous neoplasms. *Cancer* 1974;33:82-102.
- [7]. Verma KK, Ovung EM. Epidermal and sebaceous nevi treated with carbon dioxide laser. *Indian J Dermatol* 2002;68:23-4.
- [8]. Weng CJ, Tsai YC, Chen TJ. Jadassohn's Nevus of the Head and Face. *Ann Plast Surg* 1990; 25:100-2.
- [9]. Jonathan SD. Epidermal nevus. *Dermatol Online J* 2001;7:14
- [10]. Ng WK. Nevus sebaceous and apocrine differentiation. *Am J Dermatopathol* 1996;18:420-3.
- [11]. Cribier B, Scrivener YG. Tumors arising in nevus sebaceous: A study of 596 cases. *J Am Acad Dermatol* 2000; 42:263-8.
- [12]. Alsaad KO. Skin adnexal neoplasms-Part I: An approach to tumors of pilosebaceous unit. *J Clin Pathol* 2007;60:129-44.
- [13]. Kaddu S. Malignant neoplasms associated with Nevus Sebaceous. *Am J Dermatopathol* 1998;20:615-23.